



Anatomy and White Matter Connections of the Middle Frontal Gyrus

Robert G. Briggs¹, Yueh-Hsin Lin², Nicholas B. Daddario⁶, Sihyong J. Kim², Isabella M. Young³, Michael Y. Bai², Vukshitha Dhanaraj², R. Dineth Fonseka², Jorge Hormovas², Onur Tanglay², Arpan R. Chakraborty⁴, Ty M. Milligan⁴, Carol J. Abraham⁴, Christopher D. Anderson⁴, Ali H. Palejwala⁴, Andrew K. Conner⁴, Daniel L. O'Donoghue⁵, Michael E. Sughrue²

■ **BACKGROUND:** The middle frontal gyrus (MFG) is involved in attention, working memory, and language-related processing. A detailed understanding of the subcortical white matter tracts connected within the MFG can facilitate improved navigation of white matter lesions in and around this gyrus and explain the postoperative morbidity after surgery. We aimed to characterize the fiber tracts within the MFG according to their connection to neuroanatomic structures through the use of diffusion spectrum imaging-based fiber tractography and validate the findings by gross anatomic dissection for qualitative visual agreement.

■ **METHODS:** Tractography analysis was completed using diffusion imaging data from 10 healthy, adult subjects enrolled in the Human Connectome Project. We assessed the MFG as a whole component according to its fiber connectivity with other neural regions. Mapping was completed on all tracts within both hemispheres, with the resultant tract volumes used to calculate a lateralization index. A modified Klingler technique was used on 10 postmortem dissections to demonstrate the location and orientation of the major tracts.

■ **RESULTS:** Two major connections of the MFG were identified: the superior longitudinal fasciculus, which

connects the MFG to parts of the inferior parietal lobule, posterior temporal lobe, and lateral occipital cortex; and the inferior fronto-occipital fasciculus, which connected the MFG to the lingual gyrus and cuneus. Intra- and intergyral short association, U-shaped fibers were also identified.

■ **CONCLUSIONS:** Subcortical white matter pathways integrated within the MFG include the superior longitudinal fasciculus and inferior fronto-occipital fasciculus. The MFG is implicated in a variety of tasks involving attention and memory, making it an important cortical region. The postoperative neurologic outcomes related to surgery in and around the MFG could be clarified in the context of the anatomy of the fiber bundles highlighted in the present study.

INTRODUCTION

As our understanding of the frontal lobe has increased, it has become clear that its prefrontal, premotor, and motor subdivisions serve specific functions.¹ It has been found that the middle frontal gyrus (MFG) is an important center facilitating attentional processes.²⁻⁵ Human neuroimaging and animal lesion studies have demonstrated that this area plays a

Key words

- Connectome
- MFG
- Middle frontal gyrus
- Neurology
- Neurosurgery
- White matter

Abbreviations and Acronyms

- AF:** Arcuate fasciculus
- DAN:** Dorsal attention network
- DTI:** Diffusion tensor imaging
- fMRI:** Functional magnetic resonance imaging
- IFOF:** Inferior fronto-occipital fasciculus
- LI:** Lateralization index
- MFG:** Middle frontal gyrus
- ROI:** Region of interest
- SLF:** Superior longitudinal fasciculus
- UF:** Uncinate fasciculus

VAN: Ventral attention network

From the ¹Department of Neurosurgery, University of Southern California, Los Angeles, California, USA; ²Centre for Minimally Invasive Neurosurgery, Prince of Wales Private Hospital, Sydney, New South Wales, Australia; ³Cingulum Research, Cingulum Health, Sydney, New South Wales, Australia; Departments of ⁴Neurosurgery and ⁵Cell Biology, University of Oklahoma Health Science Center, Oklahoma City, Oklahoma, USA; and ⁶Rutgers Robert Wood Johnson School of Medicine, Rutgers University, New Brunswick, New Jersey, USA

To whom correspondence should be addressed: Michael E. Sughrue, M.D.
[E-mail: sughruevs@gmail.com]

Citation: *World Neurosurg.* (2021) 150:e520-e529.

<https://doi.org/10.1016/j.wneu.2021.03.045>

Journal homepage: www.journals.elsevier.com/world-neurosurgery

Available online: www.sciencedirect.com

1878-8750/\$ - see front matter © 2021 Published by Elsevier Inc.

critical role in the reorienting of attention, working memory, and speech and language comprehension.⁶⁻¹¹

Recent improvements in functional knowledge regarding the MFG should benefit clinical management and surgical decisions. Similar information has been provided for the speech and motor areas, enabling intraoperative speech and motor mapping to prevent deficits postoperatively.¹² However, little knowledge or standardization is available concerning the intraoperative tests that can be applied to prevent attentional and working memory deficits after brain surgery owing to their complexities. Thus, an immediate need exists to acquire the precise structural and functional data underlying these processes according to the cortical–subcortical connections that the operating neurosurgeon can easily apply during cerebral surgery to prevent these deficits.¹³

In the present study, we investigated the anatomic organization of the white matter fiber bundles connecting to the MFG and elucidated its functional relevance. Through diffusion spectrum imaging (DSI)-based fiber tracking and validation of the information using gross anatomic dissection for qualitative visual agreement, we have described the tracks arising within the MFG according to their connections to other brain cortices. We hypothesized that an improved understanding of the cortical white matter pathways of the MFG could be applied in multimodal navigation of white matter lesions in this region to help preserve patient function, given evidence that DSI-based neuronavigation facilitates the preservation of relevant cortical connections to decrease post-operative deficits.^{13,14}

METHODS

Definition of Regions of Interest

From an anatomic perspective, the MFG is located on the lateral bank of the frontal lobe, situated between the superior and inferior frontal sulci. The gyrus extends from the frontal pole anteriorly to the precentral sulcus/precentral gyrus posteriorly. For the purposes of fiber tractography, these anatomic boundaries were used to divide the MFG into 3 regions of interest (ROIs): an anterior region occupying the frontal polar aspect of the gyrus; a posterior region extending from the precentral sulcus anteriorly; and a middle region connecting the other 2. The coronal plane was used to visualize the superior and inferior frontal sulci, and the axial and sagittal planes were used to establish the extents of the ROIs. The basic anatomy of the MFG is shown in **Figure 1**.

Tractography

Publicly available imaging data from the Human Connectome Project were obtained for the present study from the Q3 release. Diffusion imaging with corresponding T1-weighted images from 10 healthy, unrelated subjects were analyzed during fiber tracking analysis using previously described methods (subject identification numbers, 100307, 103414, 105115, 110411, 111312, 113619, 115320, 117112, 118730, 118932).¹⁵ A multishell diffusion scheme was used, including b-values equal to 1000, 2000, and 3000 s/mm², with sampling in 90 directions for each b-value. The in-plane resolution was set at 1.25 mm, and the diffusion data were reconstructed using

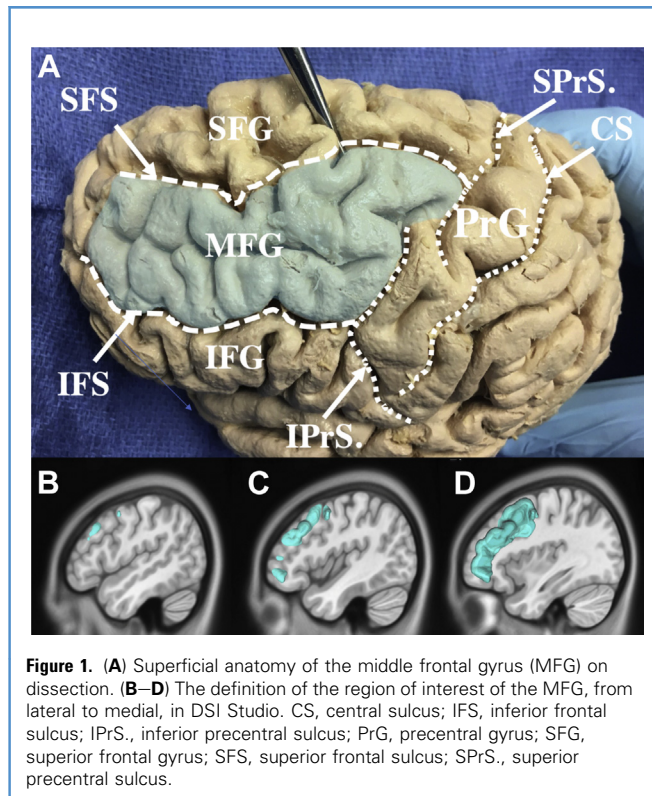


Figure 1. (A) Superficial anatomy of the middle frontal gyrus (MFG) on dissection. (B–D) The definition of the region of interest of the MFG, from lateral to medial, in DSI Studio. CS, central sulcus; IFS, inferior frontal sulcus; IPrS., inferior precentral sulcus; PrG, precentral gyrus; SFG, superior frontal gyrus; SFS, superior frontal sulcus; SPPrS., superior precentral sulcus.

generalized q-sampling imaging, with a diffusion sampling length ratio of 1.25.¹⁶

The neuroimaging studies from the subjects were compared by registering the brains to the Montreal Neurologic Institute coordinate space on a standardized brain model.¹⁷ Tractography was performed using DSI Studio (Carnegie Mellon University, Pittsburgh, Pennsylvania, USA; available at: <https://ni.cmu.edu/computing/knowledge-base/dsi-studio/>) and a ROI approach to initiate fiber tracking from a user-defined seed region was completed.¹⁸ A 2-ROI approach was used to isolate the tracts.¹⁹ To limit partial reconstructions and overestimations, the ROIs were traced with a maximum angular threshold of 45°, and the tracts were halted when a voxel was approached with no tract direction or when a direction change >45° was met. Nonrelevant tracts were excluded by using exclusion ROIs in our analyses. The tracts were identified in both hemispheres for all defined regions of the MFG.

In the present study, the MFG was divided into 3 regions: an anterior, a middle, and a posterior region. Before the cadaveric study, the tractography data for the MFG were analyzed from anteriorly to posteriorly. The lateralization indexes (LIs) were calculated using the formula (right volume – left volume)/(right volume + left volume) based on the resultant tract volumes from the identified tracts of interest.²⁰ The interhemispheric differences among the individuals were studied using an unpaired t test ($P \leq 0.05$).

Postmortem Dissection

To validate the tractography results, we sought to demonstrate the location of the white matter tracts connecting to the MFG by gross anatomic dissection for qualitative visual agreement.^{21,22} Postmortem blunt dissections were performed using a modified Klingler technique with careful preservation of the major white matter tracts of interest and both short- and long-range fibers.²³ The white matter tracts were dissected within both hemispheres. We have described our methods previously, which showed great reliability and reproducibility.²⁴⁻²⁶ The use of a modified Klingler technique preserves the myelin sheaths and axonal structures well and has demonstrated great concordance with histological analysis of the tracts.^{27,28} Relevant to our report, anatomic dissection provided a better validation method for our tractography compared with histological analyses owing to the presence of longitudinal fibers, such as the arcuate fasciculus (AF) and inferior fronto-occipital fasciculus (IFOF), which are difficult to discern with histological maps,²¹ although both methods have their limitations.²⁸ We used 10 specimens in the present study, obtained from our institution's Willard Body Program, with approval from the Oklahoma Home State Anatomic Board. All the specimens had been donated by individuals who had died of causes unrelated to intracranial pathology.

RESULTS

Long-Range Association Fibers

The MFG is structurally connected to multiple long-range white matter tracts in the brain, including the superior longitudinal

fasciculus (SLF), IFOF, AF, and uncinate fasciculus (UF). The callosal fibers were also identified, which arose within the anterior and middle thirds of the MFG in most subjects. These callosal fibers passed through the genu of the corpus callosum to terminate in the contralateral MFG. A summary of these results is presented in [Table 1](#).

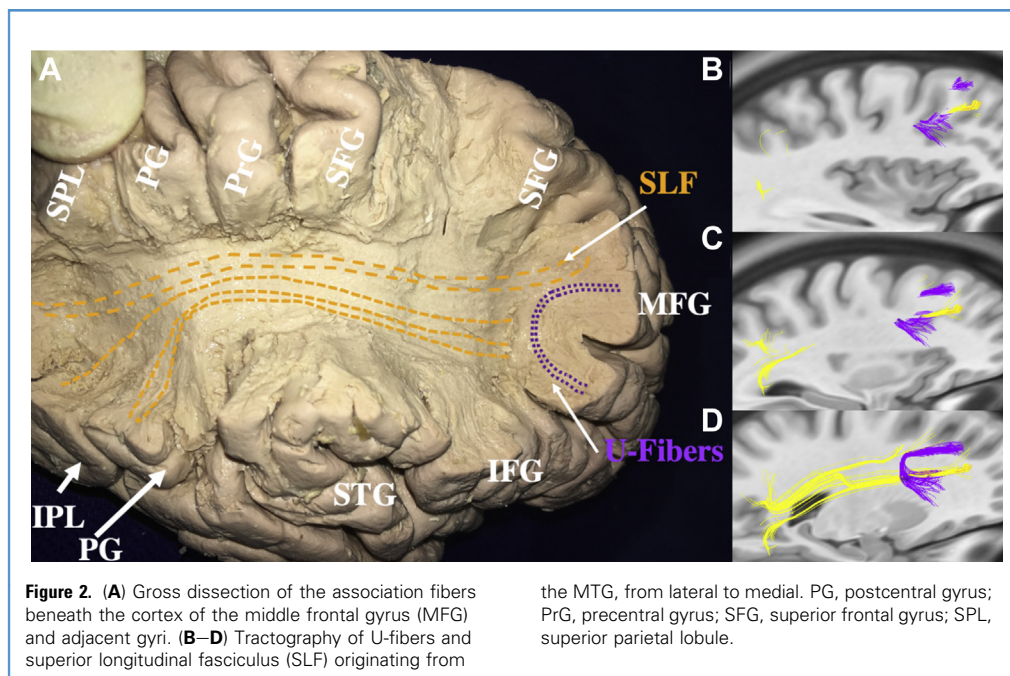
Superior Longitudinal Fasciculus. The SLF arises within the posterior one third of the MFG. The SLF fibers project deep with the posterior frontal lobe white matter, and then course posteriorly deep to the sensorimotor cortex. Parietal rami carry some of these fibers to their termination within the inferior parietal lobule at the level of the angular gyrus deep to the superior temporal sulcus. Other fibers continue their course, curving 90° inferiorly to enter the subcortical white matter of the posterior temporal lobe. The fibers then terminate in the posterior middle temporal gyrus and the lateral occipital lobe near the lateral occipital sulcus. In some subjects, the SLF connections also projected into the posterior extent of the inferior temporal gyrus. Examples of SLF fiber tractography are shown in [Figures 2](#) and [3](#). Large, non-significant variations between the left and right hemispheres were noted during SLF fiber tracking analysis ($P = 0.07$). The left and right SLF fiber bundles projected to the same cerebral regions, including the angular gyrus of the inferior parietal lobule, lateral occipital lobe, and posterior middle temporal gyrus.

Inferior Fronto-Occipital Fasciculus. The IFOF showed significant variations across all 10 subjects in the present study. In addition, a key difficulty in describing the IFOF fiber tracking results has been

Table 1. Major Connectivity of MFG and Related Speculative Function

Target	Connecting Pathway	Speculative Function
Frontal lobe		
Lateral orbitofrontal gyrus	UF, IFOF	Decision making; impulse control
Pars triangularis	AF	Syntactic, phonologic, and semantic processing
Precentral gyrus	SLF	Action selection and inhibition; fluency, prosody, and speech comprehension
Pars orbitalis	IFOF, UF	Syntactic, phonologic and semantic processing
Parietal lobe		
Postcentral gyrus	SLF	Somatosensory processing
Inferior parietal lobule	AF, SLF	Working memory (especially semantic)
Superior parietal lobule	SLF	Semantic processing; working memory; attentional processing
Supramarginal gyrus	SLF	Semantic and phonological processing; attentional processing
Temporal lobe		
Superior temporal gyrus	AF, UF	Auditory and verbal processing
Middle temporal gyrus	AF	Semantic-lexical processing; verbal memory
Inferior temporal gyrus	AF	Semantic, numerical, and emotional processing; episodic memory
Occipital lobe		
Lateral occipital lobe	IFOF	Selective visual processing; attentional processing
Pericalcarine cortex	IFOF	Selective visual processing (object processing)

MFG, middle frontal gyrus; UF, uncinate fasciculus; IFOF, inferior fronto-occipital fasciculus; AF, arcuate fasciculus; SLF, superior longitudinal fasciculus.



that the fibers could be seen arising within the frontal pole in the anterior ROI during fiber tracking analysis. All 3 frontal gyri merge at the level of the frontal pole. The left IFOF arises in the anterior third of the MFG. These fibers course inferiorly, converging at the level of the insular and opercular cortex to pass posteriorly in the extreme and external capsules of the insula. The IFOF fibers then pass laterally around the thalamus and diverge within the subcortical white matter of the posterior temporal lobe. The IFOF fibers continue to course posteriorly into the occipital lobe, eventually turning medially to end at the cuneus, lingual gyrus, and occipital pole. Examples of IFOF fiber tractography associated with the MFG are shown in [Figure 4](#). We found minimal variation between the left and right hemispheres ($P = 0.83$).

Arcuate Fasciculus. The fibers of the AF were found to travel in an anteroposterior direction, adjacent to the frontal aslant tract, with multiple terminations in the frontal, parietal, and temporal lobes. The first set of fiber terminations was in the inferior parietal lobule. Other termination regions included the inferior temporal gyrus, middle temporal gyrus, pars triangularis, and superior temporal gyrus. An example of AF tractography is shown in [Figure 3](#). We found minimal variation between the left and right hemispheres during AF fiber tracking analysis ($P = 0.53$).

Uncinate Fasciculus. The UF arises from the pars orbitalis and pars triangularis of the frontal lobe, passing through the MFG, and terminating in the superior temporal gyrus of the temporal lobe. This tract is shown in [Figure 5](#). During UF fiber tracking analysis, minimal variation between the left and right hemisphere UF tracts was noted ($P = 0.76$).

Short-Range Association Fibers

Although the MFG is associated with 2 large white matter tracts, a plethora of U-shaped fibers were also identified during fiber tractography. These unique U-shaped fibers were demonstrated by the gross anatomic dissection ([Figure 2](#)). The intergyral fibers between the MFG and precentral, superior, and inferior frontal gyri were clearly demonstrated, as were the intragyral fibers connecting different parts of the MFG. These types of fibers were identified throughout the extent of the gyrus, from the posterior boundary at the precentral sulcus to the anterior frontal pole. The U-shaped fibers identified each exhibited a similar, characteristic shape. They arose within 1 area of the cortex and then curved 180° to pass under a sulcal structure and subsequently to terminate in an area of cortex immediately adjacent to its origin.

Lateralization Indexes

The LIs comparing the SLF, IFOF, AF, and UF between the 2 hemispheres during the fiber tracking analysis are listed in [Table 2](#). Some bilateral differences in the LIs were noted in the long-range association tracts arising in the MFG.

DISCUSSION

Previous connectomic approaches have focused on mapping the brain as a single network in full microstructural detail.²⁹ In contrast, in our study, we focused on the macroscopic connectivity and fiber tracts of the MFG, a part of the cortex involved in multiple white matter pathways. Functional preservation of cortical networks during cerebral surgery is in part dependent on preserving the connections between the components of these networks.^{13,30} Therefore, the neurological

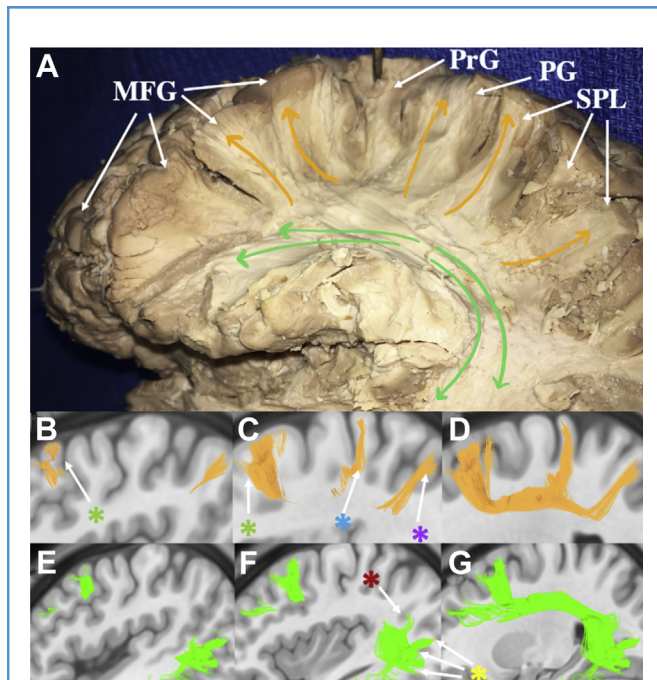


Figure 3. White matter anatomy of the superior longitudinal fasciculus (SLF) and arcuate fasciculus (AF), which originate from the middle frontal gyrus (MFG). **(A)** Gross anatomy dissection of white matter fibers. The AF (green arrows) originates from the MFG and travels posteriorly to the end of the Sylvian fissure and then descends toward the temporal lobe. The SLF originates from the MFG, travels posteriorly, and ascends toward the adjacent gyri, including the postcentral gyrus (PG), superior parietal lobule (SPL), and inferior parietal lobule (IPL). **(B)** Tractography of the SLF that originated from the MFG showing sagittal sections from laterally to medially, highlighting the SLF, which originates from the MFG, travels posteriorly, and ascends its projections to the adjacent gyri. **(E, F)** Tractography of the AF originating from the MFG showing sagittal sections from laterally to medially, highlighting the AF, which courses at the end of the Sylvian fissure and ascends toward the temporal lobe. The green asterisk indicates SLF connecting the MFG to the precentral gyrus; blue asterisk, SLF connecting the MFG to the postcentral gyrus; purple asterisk, SLF connecting the MFG to the superior parietal lobule and supramarginal gyrus; dark red asterisk, AF connecting the MFG to the inferior parietal lobule; yellow asterisk, AF connecting the MFG to the superior, middle, and inferior temporal gyri.

complications that are caused by traumatic brain injuries or brain tumor resection transgressing major white matter tracts in this area cannot be overlooked if patients are to have intact attention, working memory, and language-related processing after surgery (Table 1). Thus, we sought to provide information regarding major MFG fiber tract connections with the surrounding cortices that can be readily applied to clinical decision making and multimodal navigation for safe resection of white matter lesions.

In the present study, we have elucidated the cortical anatomy of the MFG using diffusion tractography validated by gross anatomical dissection for qualitative visual agreement. We have discussed the major connections in this area and their functional significance in the hope of providing a guide for surgeons to safely navigate the

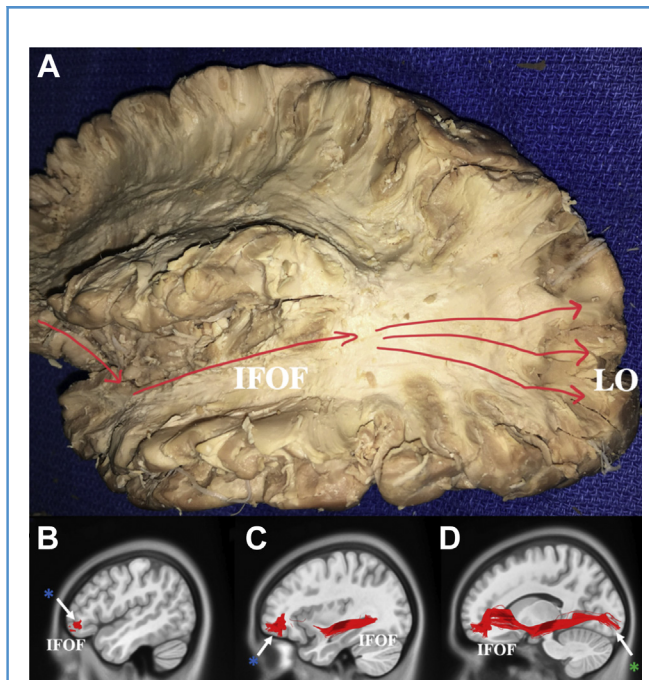


Figure 4. White matter anatomy of the inferior fronto-occipital fasciculus (IFOF). **(A)** Gross anatomy dissection of the IFOF. **(B–D)** Tractography of the IFOF originating from the middle frontal gyrus (MFG) showing the sagittal sections from laterally to medially, highlighting the IFOF, which originates from the MFG, courses inferiorly, and enters at the level of the insula and opercular cortex. The IFOF then travels laterally around the thalamus and enters the white matter at the posterior temporal lobe and then terminates at the lateral occipital lobe and pericalcarine cortex. The dark green asterisk indicates superior longitudinal fasciculus (SLF) connecting the MFG to the lateral occipital lobe and pericalcarine cortex; dark blue asterisk, IFOF connecting the MFG to the lateral orbitofrontal lobe and pars orbitalis. LO, lateral occipital lobe.

MFG during cerebral surgery and to improve our understanding of the related postoperative functional outcomes.

Functional Significance of the MFG

MFG and Attention. The MFG has been implicated in several attentional processes, including attentional reorientation.³¹ Supported by task-based activation patterns during functional magnetic resonance imaging (fMRI) studies, the right MFG has been studied extensively in the context of this attentional reorientation for unexpected stimuli.^{2,3,32} The ventral attention network (VAN) has been proposed to be responsible for bottom-up visual attentional processing in a sensory-driven fashion, and the dorsal attention network (DAN) facilitates top-down visual attentional processing in a stimulus-driven manner.³³ The right MFG is associated with ventral attentional processing and the VAN^{32,34} but has also been postulated to serve as a hub between the DAN and VAN networks to facilitate interactions between these 2 networks during attentional processing.^{3,5,9,35} Furthermore, the right MFG has been demonstrated to be linked to the ventral attention and dorsal premotor networks, composed of parcellations 8C and pg-46v and 6a,

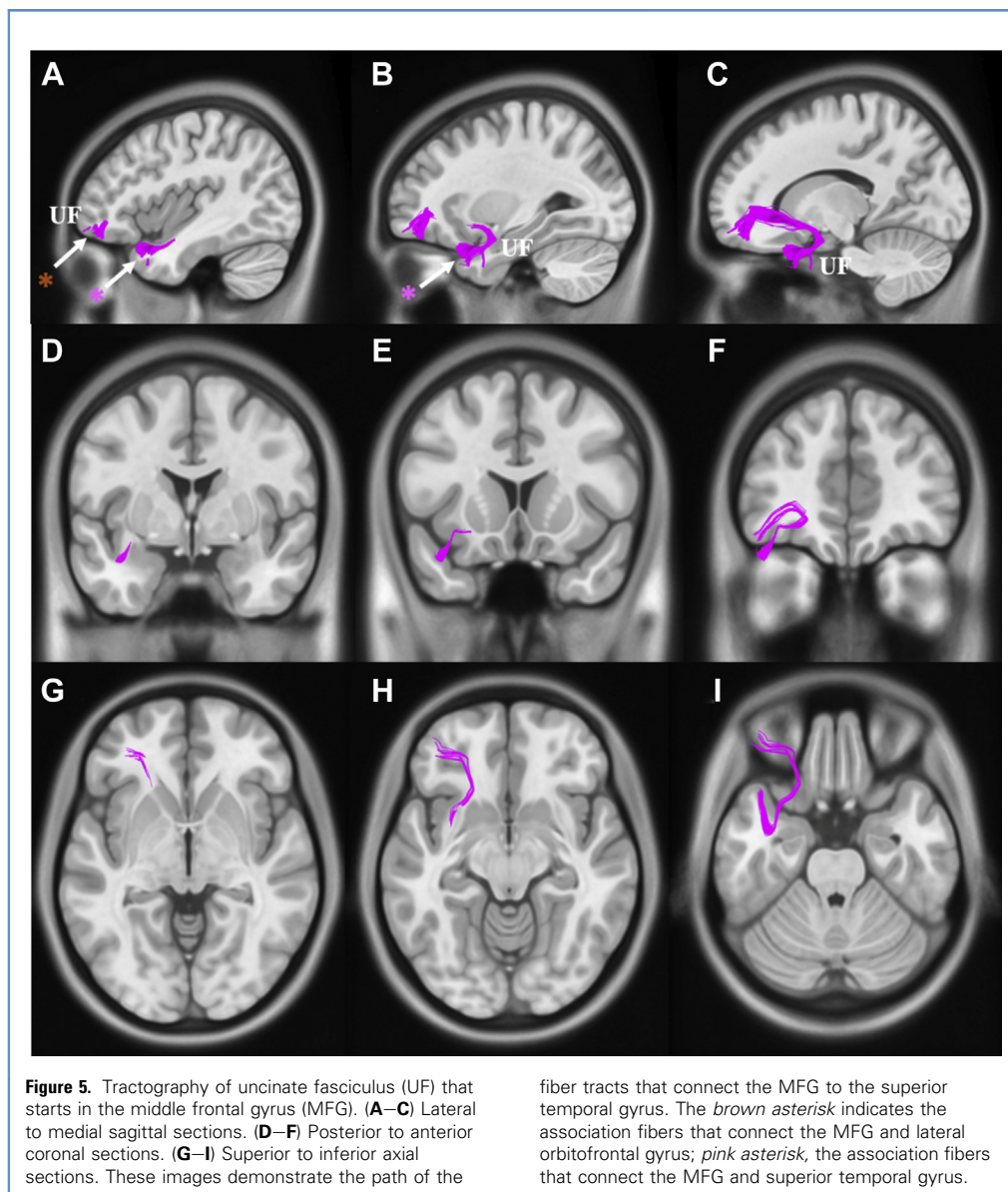


Figure 5. Tractography of uncinate fasciculus (UF) that starts in the middle frontal gyrus (MFG). (A–C) Lateral to medial sagittal sections. (D–F) Posterior to anterior coronal sections. (G–I) Superior to inferior axial sections. These images demonstrate the path of the

fiber tracts that connect the MFG to the superior temporal gyrus. The *brown asterisk* indicates the association fibers that connect the MFG and lateral orbitofrontal gyrus; *pink asterisk*, the association fibers that connect the MFG and superior temporal gyrus.

respectively.^{26,36} Given evidence showing the role of the MFG in change detection,^{37,38} the right MFG might provide a method for the brain to switch away from ongoing endogenous attentional processes to allow for reorientation to new external stimuli identified.³³

Similar to the right MFG, the left MFG is also active during attentional reorientation tasks.^{2,4,39} Although the left and right middle frontal gyri are thought to share common functions, some differences between the cerebral hemispheres have been noted. For instance, the right MFG has been proposed as a hub region for the VAN and DAN,^{3,5,9,35} while the left MFG has not. Still, others have proposed that the MFG is activated bilaterally in both the DAN and VAN, with distinct parts of the MFG participating within both networks.⁵

MFG and Working Memory. The role of the MFG in working memory is poorly understood. However, multiple fMRI studies have shown that the MFG plays a role in working memory, demonstrating the need for further investigation.⁶⁻⁸ When participants complete tasks requiring varying levels of working memory, the MFG has shown increasing fMRI activity related to an increased working memory demand and concentration.⁶⁻⁸ Nonetheless, further research is required to understand the extent of the MFG's role in working memory.

Left Posterior MFG and Language. The MFG has also demonstrated active involvement in both speech¹¹ and language comprehension.¹⁰ In a previous study, the MFG was used to determine language lateralization during a glioma resection

Table 2. Lateralization Index of White Matter Tracts for Middle Frontal Gyrus

Participant No.	Arcuate Fasciculus Laterality			Inferior Fronto-Occipital Fasciculus Laterality			Superior Longitudinal Fasciculus Laterality			Uncinate Fasciculus Laterality		
	R	L	LI	R	L	LI	R	L	LI	R	L	LI
1	1.22	9.02	-0.76	3.92	23.77	-0.72	0.44	0.46	-0.02	0.00	1.43	-1.00
2	32.53	0.49	0.97	54.75	0.00	1.00	1.65	0.25	0.74	0.00	5.98	-1.00
3	28.42	9.76	0.49	7.98	0.00	1.00	3.67	0.42	0.79	0.00	0.92	-1.00
4	0.30	28.16	-0.98	0.00	0.00	0.00	2.80	0.28	0.82	26.47	6.98	0.58
5	6.41	31.25	-0.66	0.00	0.00	0.00	7.35	2.41	0.51	0.00	0.45	-1.00
6	0.00	20.85	-1.00	1.36	2.04	-0.20	3.49	0.29	0.85	0.00	1.20	-1.00
7	0.54	13.11	-0.92	0.00	20.67	-1.00	5.42	1.43	0.58	0.00	5.17	-1.00
8	5.40	0.57	0.81	7.48	23.29	-0.51	1.64	1.13	0.18	0.00	0.00	0.00
9	0.00	0.00	0.00	31.00	53.44	0.00	12.78	1.89	0.00	8.53	2.53	0.00
10	0.00	0.98	-1.00	1.20	0.00	1.00	0.68	0.44	0.21	0.00	2.89	-1.00
Average	7.48	11.42	-0.21	10.77	12.32	-0.07	3.99	0.90	0.63	3.50	2.75	0.12
P value	0.53			0.83			0.07			0.76		

R, right hemisphere; L, left hemisphere; LI, lateralization index (calculated from resultant tract volumes using the formula $[\text{right volume} - \text{left volume}] / [\text{right volume} + \text{left volume}]$).

involving the Broca area,⁴⁹ showing that the MFG is comparable to the Broca area in terms of its ability to determine hemispheric dominance for language. Further evidence of the MFG's role in language and speech comprehension can be seen from the activations of the MFG during semantic priming tasks.⁴¹⁻⁴⁴ In a semantic priming task involving repeated words, an increase in the fMRI blood oxygenation level-dependent signaling of the right MFG was noted.⁴² The investigators noted this might have resulted from the previous recognition of the words,⁴² because, as previously discussed, the MFG plays some role in working memory. Further evidence has implicated a possible role of the MFG in lexical decision making,⁴⁵ showing a greater peak of activation in related conditions of prime target pairs than in unrelated conditions.

Use of LIs in the Present Study

The LI is a useful measure of hemispheric dominance and is particularly relevant in anatomical discussions of the MFG white matter tracts. Historically, the domain of hemispheric laterality has been studied, especially in the processing of language. In our study, the LI was used to ascertain any hemispheric asymmetry in the white matter tracts of the MFG. Significant right hemispheric dominance was found for the SLF (Table 2). This might be related to the SLF's involvement in the communication between the MFG and the VAN, which has been proposed to be lateralized to the right hemisphere in previous fMRI studies.⁴⁶ However, it is important to note that the true presence and extent of any functional asymmetries of the VAN and DAN across the 2 hemispheres remains largely unclear. However, the left lateralization of the language domain has been widely accepted by the scientific

community. This coincides with the findings showing left hemispheric dominance for both AF and IFOF, fibers that have been associated with various language hubs and networks (Table 2). However, this finding in our present study was statistically insignificant; thus, future studies exploring the anatomical basis of hemispheric lateralization of white matter tracts are needed.

Surgical Relevance

As discussed, the reported data have suggested that damage to white matter tracts of the MFG during neurosurgical intervention can lead to profound neurological deficits. A pre- and post-operative analysis of 2 patients using diffusion tensor imaging (DTI) tractography revealed new-onset or worsened spatial neglect after the right SLF at the inferior parietal lobe had been cut during resection of a tumor at the trigone of the lateral ventricle.⁴⁷ This might be related to the important anatomical role the SLF plays in allowing for communication between the MFG and parietal cortex, which was found in the present study.

Furthermore, surgical approaches toward the temporal stem can damage the IFOF, which previously was found to subserve the ventral stream of language processing. The implications of an IFOF lesion have thus presented themselves through a variety of language deficits, including semantic and phonological paraphasia elicited through intraoperative electrical stimulation and voxel-based lesion-symptom mapping analyses in previous replicative studies.⁴⁸

Pure apraxia of speech can occur from damage near the pre-central gyrus or premotor area, albeit rather uncommonly.^{49,50} However, we have previously elucidated that resection of the

posterior MFG will also lead to pure apraxia of speech.⁵¹ In our patient, despite the patient's significantly impaired fluency and increasing difficulty with increasing word lengths and polysyllabic words,⁵² custom language and articulatory assessments determined that the comprehension and naming abilities had remained intact in the patient. These data further implicate the complex role of the MFG in lexical and phonetic processing.⁵³

Future Directions

Knowledge of the relevant fiber tracts surrounding white matter lesions allows the surgeon to create a safe surgical corridor that can be followed to maximize the extent of resection and also prevent neurologic deficits.¹³ The anatomic information and tractography elucidated in the present study can be applied to multimodal navigation when resecting lesions within the MFG and neighboring cortices to prevent unnecessary transgression of relevant white matter connections that underlie functions such as semantic processing and speech. We have elucidated the long-range connections between the MFG, intraparietal sulcus, and supramarginal gyrus via the SLF fibers and the connections between the MFG and temporal lobe via the AF fibers (Figure 3). In this context, when performing cerebral surgery in the frontal or temporal lobes, a more angular approach, instead of a straight up and down cut could protect the SLF and AF fibers originating from the MFG, to prevent an array of postoperative aphasia syndromes.^{13,51,54}

With added multimodal navigation or tools such as tractography, the tendency to overresect brain tissue could be increased owing to the additional knowledge of eloquent and noneloquent cortical matter. This increased resection could result in additional immediate postoperative deficits not otherwise present owing to disrupted parenchyma and edema. However, the added benefit of accurate structural and functional perioperative information on white matter tracts might ultimately benefit long-term neurocognition, motor skills, and overall recovery.⁵⁵

Study Limitations

The present study included only 10 subjects because we did not expect significant inter-individual differences in the MFG tract anatomy. Significant variation across the 10 subjects was only found in the inspection of the IFOF. Although the present study served as an inquisitive initial investigation into the tractography of the MFG, follow-up studies with larger sample populations are

warranted to explore the anatomical differences among subjects and their significance on the nature of our present results.

Furthermore, although postmortem dissections can provide ex vivo validation of tractography analyses by qualitative visual agreement as employed in our study,^{21,22} postmortem dissections and DTI are limited in their ability to identify small crossing fibers owing to damage from the dissection and limited technological advancements. However, in the present study, we used DSI, which maps the 3-dimensional probability density function of water diffusion at each voxel and is superior to DTI for identifying crossing fibers.⁵⁶ Concomitant uses of other algorithms such as spherical deconvolution methods might further overcome these limitations.⁵⁷ Nonetheless, in relationship to the present study, both gross anatomic dissection and DSI-based tractography are superior to histological maps in their ability to identify longitudinal fibers such as the AF and IFOF, possibly because of the current difficulty with postmortem myelin staining procedures.^{21,28} Future studies should perform further functional investigation to refine our cortical model of the MFG.

CONCLUSIONS

The MFG is a highly interconnected cortical structure involved in a variety of tasks, including attentional processing, working memory, and language production and comprehension. The results from the present study have elucidated the underlying white matter anatomy of the MFG and the cerebral networks amalgamating at the MFG, with the ultimate goal of providing improved understanding of neuro-oncological outcomes after cerebral surgery within these cortical areas.

CRedit AUTHORSHIP CONTRIBUTION STATEMENT

Robert G. Briggs: Investigation. **Yueh-Hsin Lin:** Formal analysis, Writing - original draft. **Nicholas B. Dadario:** Writing - original draft. **Sihyong J. Kim:** Writing - review & editing, Visualization. **Isabella M. Young:** Writing - review & editing, Supervision. **Michael Y. Bai:** Investigation. **Vukshitha Dhanaraj:** Investigation. **R. Dineth Fonseka:** Formal analysis, Resources. **Jorge Hormovas:** Software. **Onur Tanglay:** Visualization, Formal analysis. **Arpan R. Chakraborty:** Validation. **Ty M. Milligan:** Visualization, Validation. **Carol J. Abraham:** Methodology. **Christopher D. Anderson:** Data curation. **Ali H. Palejwala:** Data curation. **Andrew K. Conner:** Project administration. **Daniel L. O'Donoghue:** Methodology, Resources. **Michael E. Sughrue:** Conceptualization, Supervision.

REFERENCES

- Alvarez JA, Emory E. Executive function and the frontal lobes: a meta-analytic review. *Neuropsychol Rev.* 2006;16:17-42.
- Thiel CM, Zilles K, Fink GR. Cerebral correlates of alerting, orienting and reorienting of visuospatial attention: an event-related fMRI study. *Neuroimage.* 2004;21:318-328.
- Japee S, Holiday K, Satyshur MD, Mukai I, Ungerleider LG. A role of right middle frontal gyrus in reorienting of attention: a case study. *Front Syst Neurosci.* 2015;9:23.
- Thiel CM, Fink GR. Effects of the cholinergic agonist nicotine on reorienting of visual spatial attention and top-down attentional control. *Neuroscience.* 2008;152:381-390.
- Corbetta M, Patel G, Shulman GL. The reorienting system of the human brain: from environment to theory of mind. *Neuron.* 2008;58:306-324.
- Yin L, Reuter M, Weber B. Let the man choose what to do: neural correlates of spontaneous lying and truth-telling. *Brain Cogn.* 2016;102:13-25.
- Klingberg T, O'Sullivan BT, Roland PE. Bilateral activation of fronto-parietal networks by incrementing demand in a working memory task. *Cereb Cortex.* 1997;7:465-471.
- Vartanian O, Kwantes P, Mandel D, et al. Right inferior frontal gyrus activation as a neural marker of successful lying. *Front Hum Neurosci.* 2013;7:616.
- Fox MD, Corbetta M, Snyder AZ, Vincent JL, Raichle ME. Spontaneous neuronal activity distinguishes human dorsal and ventral attention systems. *Proc Natl Acad Sci.* 2006;103:10046-10051.
- Zaca D, Jarso S, Pillai JJ. Role of semantic paradigms for optimization of language mapping in clinical fMRI studies. *AJNR Am J Neuroradiol.* 2013;34:1966-1971.

11. Yue Q, Zhang L, Xu G, Shu H, Li P. Task-modulated activation and functional connectivity of the temporal and frontal areas during speech comprehension. *Neuroscience*. 2013;237:87-95.
12. Saito T, Muragaki Y, Maruyama T, Tamura M, Nitta M, Okada Y. Intraoperative functional mapping and monitoring during glioma surgery. *Neurol Med Chir (Tokyo)*. 2015;55:1-13.
13. Briggs RG, Allan PG, Poologaindran A, et al. The frontal aslant tract and supplementary motor area syndrome: moving towards a connectomic initiation axis. *Cancers (Basel)*. 2021;13:1116.
14. Wu JS, Zhou LF, Tang WJ, et al. Clinical evaluation and follow-up outcome of diffusion tensor imaging-based functional neuronavigation: a prospective, controlled study in patients with gliomas involving pyramidal tracts. *Neurosurgery*. 2007;61:935-948 [discussion: 948-949].
15. Burks JD, Bonney PA, Conner AK, et al. A method for safely resecting anterior butterfly gliomas: the surgical anatomy of the default mode network and the relevance of its preservation. *J Neurosurg*. 2016;126:1795-1811.
16. Yeh F-C, Wedeen VJ, Tseng W-YI. Generalized q-sampling imaging. *IEEE Trans Med Imaging*. 2010;29:1626-1635.
17. Evans AC, Marrett S, Neelin P, et al. Anatomical mapping of functional activation in stereotactic coordinate space. *Neuroimage*. 1992;1:43-53.
18. Martino J, Hamer PCDW, Berger MS, et al. Analysis of the subcomponents and cortical terminations of the perisylvian superior longitudinal fasciculus: a fiber dissection and DTI tractography study. *Brain Struct Funct*. 2013;218:105-121.
19. Kamali A, Sair HI, Radmanesh A, Hasan KM. Decoding the superior parietal lobule connections of the superior longitudinal fasciculus/arcuate fasciculus in the human brain. *Neuroscience*. 2014;277:577-583.
20. De Schotten MT, Dell'Acqua F, Forkel SJ, et al. A lateralized brain network for visuospatial attention. *Nat Neurosci*. 2011;14:1245.
21. Catani M, Dell'Acqua F, Bizzi A, et al. Beyond cortical localization in clinico-anatomical correlation. *Cortex*. 2012;48:1262-1287.
22. Catani M, Howard RJ, Pajevic S, Jones DK. Virtual in vivo interactive dissection of white matter fasciculi in the human brain. *Neuroimage*. 2002;17:77-94.
23. Koutsarnakis C, Liakos F, Kalyvas AV, Sakas DE, Stranjalis G. A laboratory manual for stepwise cerebral white matter fiber dissection. *World Neurosurg*. 2015;84:483-493.
24. Palejwala AH, O'Connor KP, Milton CK, et al. Anatomy and white matter connections of the fusiform gyrus. *Sci Rep*. 2020;10:13489.
25. Palejwala AH, O'Connor KP, Pelargos P, et al. Anatomy and white matter connections of the lateral occipital cortex. *Surg Radiol Anat*. 2020;42:315-328.
26. Sheets JR, Briggs RG, Bai MY, et al. Parcellation-based modeling of the dorsal premotor area. *J Neurol Sci*. 2020;415:116907.
27. Zemmoura I, Blanchard E, Raynal P-I, Rousselot-Denis C, Destrieux C, Velut S. How Klingler's dissection permits exploration of brain structural connectivity? An electron microscopy study of human white matter. *Brain Struct Funct*. 2016;221:2477-2486.
28. Thiebaut de Schotten M, Ffytche DH, Bizzi A, et al. Atlasing location, asymmetry and inter-subject variability of white matter tracts in the human brain with MR diffusion tractography. *Neuroimage*. 2011;54:49-59.
29. Van Essen DC, Smith SM, Barch DM, Behrens TE, Yacoub E, Ugurbil K. The WU-Minn Human Connectome Project: an overview. *Neuroimage*. 2013;80:62-79.
30. Duffau H. The challenge to remove diffuse low-grade gliomas while preserving brain functions. *Acta Neurochir*. 2012;154:569-574.
31. Milham MP, Banich MT, Webb A, et al. The relative involvement of anterior cingulate and prefrontal cortex in attentional control depends on nature of conflict. *Cogn Brain Res*. 2001;12:467-473.
32. Corbetta M, Shulman GL. Control of goal-directed and stimulus-driven attention in the brain. *Nat Rev Neurosci*. 2002;3:201.
33. Japee S, Holiday K, Satyshur MD, Mukai I, Ungerleider LG. A role of right middle frontal gyrus in reorienting of attention: a case study. *Front Syst Neurosci*. 2015;9:23.
34. Shulman GL, Astafiev SV, Franke D, et al. Interaction of stimulus-driven reorienting and expectation in ventral and dorsal fronto-parietal and basal ganglia-cortical networks. *J Neurosci*. 2009;29:4392-4407.
35. He BJ, Snyder AZ, Vincent JL, Epstein A, Shulman GL, Corbetta M. Breakdown of functional connectivity in frontoparietal networks underlies behavioral deficits in spatial neglect. *Neuron*. 2007;53:905-918.
36. Allan PG, Briggs RG, Conner AK, et al. Parcellation-based tractographic modeling of the ventral attention network. *J Neurol Sci*. 2020;408:116548.
37. Kuo B-C, Yeh Y-Y, Chen D-Y, Liang KC, Chen J-H. The capacity constraint in the prefrontal and parietal regions for coordinating dual arithmetic tasks. *Brain Res*. 2008;1199:100-110.
38. Yeh Y-Y, Kuo B-C, Liu H-L. The neural correlates of attention orienting in visuospatial working memory for detecting feature and conjunction changes. *Brain Res*. 2007;1130(suppl C):146-157.
39. Vossel S, Thiel CM, Fink GR. Cue validity modulates the neural correlates of covert endogenous orienting of attention in parietal and frontal cortex. *Neuroimage*. 2006;32:1257-1264.
40. Dong JW, Brennan NM, Izzo G, Peck KK, Holodny AI. fMRI activation in the middle frontal gyrus as an indicator of hemispheric dominance for language in brain tumor patients: a comparison with Broca's area. *Neuroradiology*. 2016;58:513-520.
41. Laufer I, Negishi M, Lacadie CM, Papademetris X, Constable RT. Dissociation between the activity of the right middle frontal gyrus and the middle temporal gyrus in processing semantic priming. *PLoS One*. 2011;6:e22368.
42. Raposo A, Moss HE, Stamatakis EA, Tyler LK. Repetition suppression and semantic enhancement: an investigation of the neural correlates of priming. *Neuropsychologia*. 2006;44:2284-2295.
43. Sachs O, Weis S, Zellagui N, et al. Automatic processing of semantic relations in fMRI: neural activation during semantic priming of taxonomic and thematic categories. *Brain Res*. 2008;1218(suppl C):194-205.
44. Sachs O, Weis S, Zellagui N, et al. How different types of conceptual relations modulate brain activation during semantic priming. *J Cogn Neurosci*. 2011;23:1263-1273.
45. Rissman J, Eliassen JC, Blumstein SE. An event-related fMRI investigation of implicit semantic priming. *J Cogn Neurosci*. 2003;15:1160-1175.
46. Vossel S, Fink GR. Contralateral distractors enhance ipsilesional target processing after right-hemispheric stroke. *Cortex*. 2016;78:115-124.
47. Shinoura N, Suzuki Y, Yamada R, Tabei Y, Saito K, Yagi K. Damage to the right superior longitudinal fasciculus in the inferior parietal lobe plays a role in spatial neglect. *Neuropsychologia*. 2009;47:2600-2603.
48. Almairac F, Herbet G, Moritz-Gasser S, de Champfleure NM, Duffau H. The left inferior fronto-occipital fasciculus subserves language semantics: a multilevel lesion study. *Brain Struct Funct*. 2015;220:1983-1995.
49. Itabashi R, Nishio Y, Kataoka Y, et al. Damage to the left precentral gyrus is associated with apraxia of speech in acute stroke. *Stroke*. 2016;47:31-36.
50. Patira R, Ciniglia L, Calvert T, Altschuler EL. Pure apraxia of speech due to infarct in premotor cortex. *Neurol Neurochir Pol*. 2017;51:519-524.
51. Chang EF, Kurteff G, Andrews JP, et al. Pure apraxia of speech after resection based in the posterior middle frontal gyrus. *Neurosurgery*. 2020;87:E383-E389.
52. Haley KL, Overton HB. Word length and vowel duration in apraxia of speech: the use of relative measures. *Brain Lang*. 2001;79:397-406.

53. Davis MH, Di Betta AM, Macdonald MJE, Gaskell MG. Learning and consolidation of novel spoken words. *J Cogn Neurosci*. 2009;21:803-820.
54. Glasser MF, Rilling JK. DTI tractography of the human brain's language pathways. *Cereb Cortex*. 2008;18:2471-2482.
55. González-Darder JM, González-López P, Talamantes F, et al. Multimodal navigation in the functional microsurgical resection of intrinsic brain tumors located in eloquent motor areas: role of tractography. *Neurosurg Focus*. 2010;28:E5.

56. Wedeen VJ, Wang RP, Schmahmann JD, et al. Diffusion spectrum magnetic resonance imaging (DSI) tractography of crossing fibers. *Neuroimage*. 2008;41:1267-1277.
57. Catani M, Dell'Acqua F, Vergani F, et al. Short frontal lobe connections of the human brain. *Cortex*. 2012;48:273-291.

Conflict of interest statement: Michael Sughrae is the Chief Medical Officer for Omniscient Neurotechnologies but no products directly related to this were discussed in the present report.

Received 19 February 2021; accepted 9 March 2021

*Citation: World Neurosurg. (2021) 150:e520-e529.
<https://doi.org/10.1016/j.wneu.2021.03.045>*

Journal homepage: www.journals.elsevier.com/world-neurosurgery

Available online: www.sciencedirect.com

1878-8750/\$ - see front matter © 2021 Published by Elsevier Inc.